

**PATIENT**

Wendy Ball

**SPECIES**

Canine

**BREED**

Chihuahua

**SEX**

FS

**AGE**

10yr

**WEIGHT**

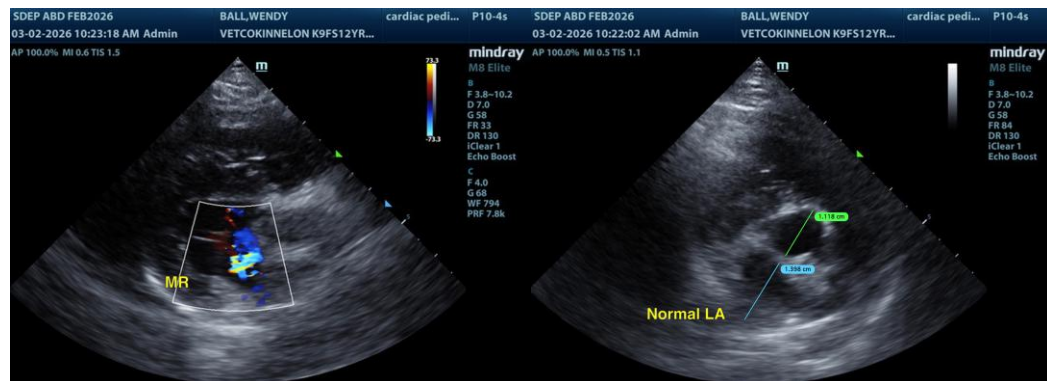
10lb

**INTERPRETATION OF THE FINDINGS & FURTHER RECOMMENDATIONS**

Similar cardiac presentation compared to the previous study without evidence of progression. The continued lack of LA enlargement indicates the current and future risk of complication secondary to MR remains low. Continued Vetmedin and antitussive medication would be appropriate. No indication for additional cardiac medication.

The prognosis remains variable and sonographic monitoring is advised. Recheck echo suggested in 6-12 months, sooner if clinically indicated.

Anesthetic risk is considered mild. Suggested anesthetic protocol may include opioid or Benzodiazepine pre-med, induction with Propofol or Alfaxalone, and appropriate gas anesthesia with avoidance of alpha 2 agonists.



**INTERPRETED BY**

R. McKenzie Daniel, DVM, DABVP (Canine and Feline)

**IMAGING PERFORMED BY**

Kerri Becker

**HOSPITAL NAME**

Vetco Kinnelon

**REFERRING VET**

Dr Griffin

**INVOICE 24086**

**DATE 03/02/2026**

The information and recommendations provided are based on the images presented by the referring veterinarian/sonographer. No evaluation can be communicated regarding pathology that was not visible in the image/video clips provided.

Thank you for this referral. If the clinical or image interpretation does not parallel your findings or if I can be of any further assistance, please contact me.

R. McKenzie Daniel, DVM, DABVP (Canine/Feline Practice)  
[info@sonopath.com](mailto:info@sonopath.com)